

# Lymphatic Mapping and Sentinel Node Analysis: Current Concepts and Applications

Steven L. Chen, MD, MBA; Douglas M. Iddings, DO; Randall P. Scheri, MD;  
Anton J. Bilchik, MD, PhD, FACS

**Dr. Chen** is Fellow in Surgical Oncology, John Wayne Cancer Institute, Santa Monica, CA.

**Dr. Iddings** is Fellow in Surgical Oncology, John Wayne Cancer Institute, Santa Monica, CA.

**Dr. Scheri** is Fellow in Surgical Oncology, John Wayne Cancer Institute, Santa Monica, CA.

**Dr. Bilchik** is Director, Gastrointestinal Program; Director of Gastrointestinal Surgical Oncology, John Wayne Cancer Institute, Santa Monica, CA.

This article is available online at <http://CAonline.AmCancerSoc.org>

**ABSTRACT** Since the introduction of sentinel node biopsy in 1990 as a minimally invasive surgical technique for the diagnosis of melanoma lymphatic metastases, the number of applications has expanded. We review applications and the current status of sentinel node biopsy in melanoma, breast, colon, gastric, esophageal, head and neck, thyroid, and lung cancer. Variations on techniques specific to each organ are explained, and the current role of sentinel node biopsy in diagnosis and treatment is discussed. (*CA Cancer J Clin* 2006;56:292-309.)

© American Cancer Society, Inc., 2006.

## INTRODUCTION

The sentinel node is commonly defined as the initial lymph node to which the primary tumor drains. The reintroduction of this concept in 1990,<sup>1</sup> coupled with the ability to detect “sentinel nodes,” has radically changed the method of staging melanoma and breast cancer. The concept of sentinel lymph node (SLN) mapping assumes an orderly progression of metastatic disease from the primary tumor to the lymphatic system. It postulates that tumors drain directly to a limited number of lymph nodes in a specific lymphatic drainage basin. Use of tracers allows identification of these tumor-draining lymph nodes for further excision and analysis. Although the term *sentinel node* was introduced as an anatomic construct decades ago, the functional identification of this node was made practical by Morton, et al.<sup>2</sup> in 1992. Their seminal report used isosulfan blue dye to intraoperatively map the pathway from a primary cutaneous melanoma to one or more SLNs in the regional lymphatic basin. Biopsy and analysis of SLNs accurately reflected the tumor status of the entire lymphatic basin.

After that initial report, the technique has been refined, and its indications have expanded. Giuliano, et al.<sup>3</sup> popularized the use of sentinel node mapping in breast cancer in 1994. Since then, the sentinel node concept has been tested in a number of tumors with varying success. This article reviews the development of sentinel node mapping and discusses its current applications across a variety of tumors in which a significant amount of evidence has been accumulated.

## GENERALIZED RATIONALE FOR SENTINEL NODE MAPPING

Because the sentinel node concept implies the orderly progression of metastasis from a primary tumor to a single draining node in the relevant lymph node basin, it has little relevance in tumors that are primarily spread through hematogenous routes. In lymphatically spread tumors, however, it can identify tumor-bearing nodes with great accuracy. This basic framework generates three primary reasons for sentinel node biopsy: (1) to minimize the morbidity of lymph node assessment, (2) to alter the surgical procedure performed, and/or (3) to improve the accuracy of the nodal assessment.

Sentinel lymph node biopsy (SLNB) was initially developed as a minimally invasive surgical alternative to routine (elective) complete lymphadenectomy. Until the development of this technique, significant controversy existed as to the selection of patients who needed full lymph node dissections in the setting of clinically negative nodes. The

incidence of complications, most prominently lymphedema, had to be balanced against the additional staging information that was available by complete nodal evaluation. Although SLNB is not without morbidity, as shown in the recent report from the American College of Surgeons (ACoS) Oncology Group (ACOSOG) Z0010 trial,<sup>4</sup> it continues to be far less than that associated with full lymph node dissections.<sup>5,6</sup>

The development of the sentinel node technique using the gamma counter allowed the surgeon to alter the surgical procedure in real time. For example, nonextremity melanomas not infrequently drain to a different lymph node basin than the one physically closest to the lesion. Lymphoscintigraphy performed before sentinel node biopsy can demonstrate aberrant drainage to unexpected lymph node basins (Figure 1). The more routine use of lymphoscintigrams can also identify in-transit metastases (Figure 2) for melanoma and decrease the use of undirected lymph node sampling.

Another rationale presented for sentinel node identification was the ability to use adjunctive analysis methods to a limited number of lymph nodes. Typical analysis of nonsentinel lymph nodes involves the bivalving of nodes followed by hematoxylin-eosin (H&E) staining. The discovery of different types of markers and development of methods such as immunohistochemical staining for their detection has resulted in the refinement of staging classifications, as well as the possibility of upstaging tumors not detected

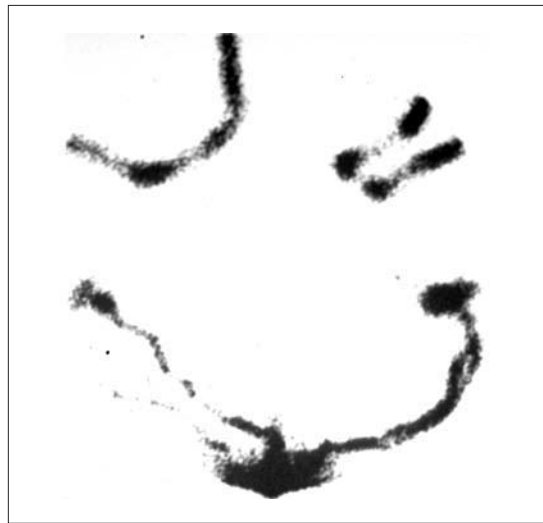

FIGURE 1 Lymphoscintigraphy of a Truncal Melanoma Tracking to Both Axilla.

on standard H&E slides. This intensive examination was previously impractical because of the large number of nodes often provided with a specimen. The sentinel node technique has allowed the application of more intensive “ultrastaging” of lymph nodes by the identification of a single or small number of nodes at high risk for metastasis. This ultrastaging has enabled pathologists to identify much smaller metastatic deposits of tumor in lymph nodes with higher sensitivity. So-called isolated tumor cells and micrometastases are now codified into the American Joint Committee on Cancer (AJCC) staging systems as substages of N0 from the tumor-node-metastasis (TNM) rubric in breast and colon

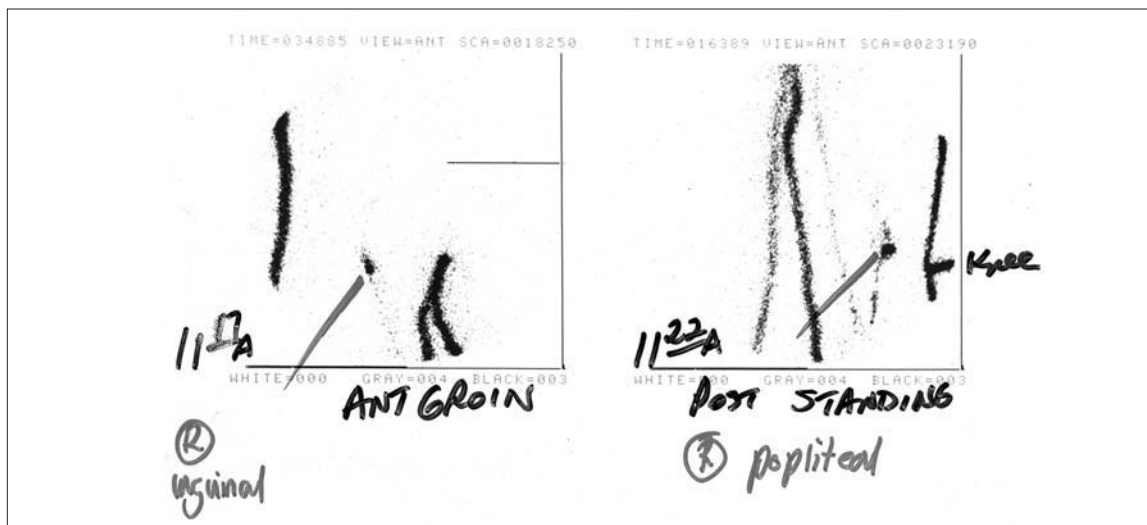


FIGURE 2 Lymphoscintigraphy of a Leg Melanoma Demonstrating a Popliteal Lymph Node.

cancers.<sup>7</sup> The reasoning for this classification is the still uncertain impact of micrometastases and isolated tumor cells on survival. Ultrastaging uses combinations of three complementary techniques: serial sectioning, immunohistochemistry (IHC), and reverse-transcriptase polymerase chain reaction (RT-PCR).

Serial sectioning of lymph nodes allows the pathologic examination of multiple levels of a given lymph node instead of the standard single level. Such examination can detect much smaller tumor deposits since sampling error is reduced. Whereas serial sectioning is not practical for the large number of nodes in a complete lymphadenectomy specimen, it can be done efficiently on the much smaller SLNB specimen.

IHC staining is far more sensitive than H&E staining in the detection of malignant cells. The development of new stains for a number of proteins specific to different tumor and tissue types has increased specificity as well. Cytokeratin IHC in breast and colon cancer and S-100 and MART-1 in melanoma have made identification of even isolated tumor cells in specimens easier (Figure 3). However, while highly sensitive, these stains can also lead to false-positives when not used carefully; for example, dendritic leukocytes also stain S-100 positive<sup>8</sup> and plasma cells can stain positive for cytokeratin.<sup>9</sup> Thus, IHC slides should be read by pathologists experienced with the characteristics of each specific stain.

RT-PCR takes advantage of the development of a variety of probes for genes that may be over-expressed in certain tumors. This technique does not rely on light microscopy, but instead relies on the expression of mRNA of these tumor markers. For melanoma, this has included tyrosinase-related proteins (TRP-1, TRP-2), microphthalmia-associated transcription factor (MITF), MAGE-3, gp100, and MART-1. These can be used singly or in multimarker panels.<sup>10,11</sup> For breast cancer, cytokeratin-19,<sup>12</sup> MUC-1,<sup>13</sup> mammaglobin B,<sup>14</sup> and MAGE-A3<sup>15</sup> have been identified as potential markers, among others. Carcinoembryonic antigen (CEA) and MAGE-A are the most frequently used in colon cancer.<sup>16</sup> The identification and amplification of these markers have allowed for very sensitive and reproducible assays for tumor cells within lymph nodes. At this time,

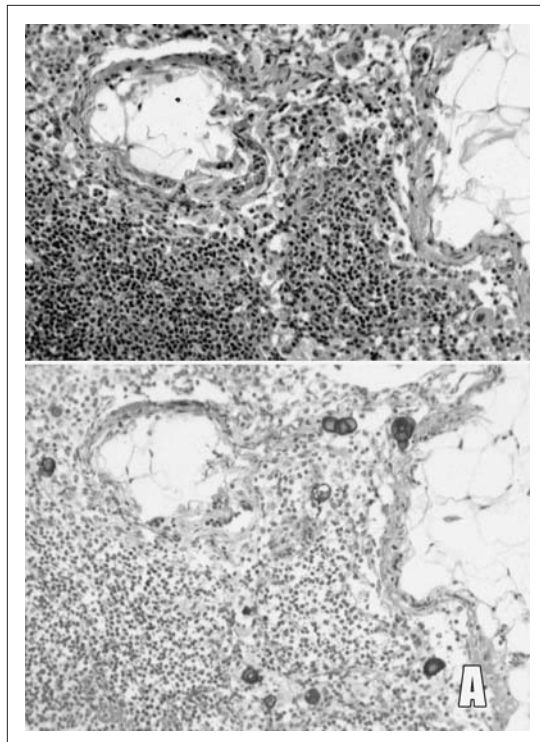


FIGURE 3 Cytokeratin Immunohistochemical Staining Demonstrating Isolated Colon Cancer Cells.

RT-PCR continues to be performed largely in research settings since the prognostic significance of a RT-PCR positive-only group is still unclear.<sup>17</sup>

The value of micrometastasis detection continues to be controversial. Results from smaller studies have been mixed as to its impact on long-term prognosis. The AJCC staging system continues to consider micrometastases detected only by IHC or RT-PCR techniques to be N0 disease, albeit labeled as pN0(i+) or pN0(mol+) to denote their presence.

#### TECHNICAL OVERVIEW OF SENTINEL NODE MAPPING

The basic technique of sentinel node identification involves the injection of a tracer that identifies the lymphatic drainage pathway from a primary tumor. The earliest applications used a vital blue dye, usually isosulfan blue. Although isosulfan blue is generally safe, anaphylaxis can occur in up to 1% of patients.<sup>18</sup> Other blue dyes such as methylene blue have had similar success rates in small series.<sup>19,20</sup> Subsequent reports<sup>21</sup> describe the use of radioisotopes such

as technetium-99m ( $^{99m}\text{Tc}$ )-bound colloids for preoperative lymphoscintigraphy and intraoperative localization with a gamma probe.<sup>22,23</sup> The most commonly used radiolabeled colloid in the United States is  $^{99m}\text{Tc}$ -sulfur colloid, whereas  $^{99m}\text{Tc}$ -nanocolloid and  $^{99m}\text{Tc}$ -antimony sulfide are more commonly used in Europe and Australia, respectively.

The most common mapping technique uses a combination of blue dye and radioisotope, although excellent results have been reported with single-modality techniques in experienced hands. Briefly, an appropriate amount of tracer is injected in locations that will mimic the lymphatic drainage pattern of the tumor. After an appropriate delay, the gamma counter is used to identify the "hot spot" on the skin in the lymphatic basin identified on the lymphoscintigram. An incision is planned to reach this lymph node, keeping in mind that many clinicians will choose to re-excite this incision if a completion lymphadenectomy is deemed necessary. A limited dissection is made to identify the blue node and/or the most radioactive node. Often a blue lymphatic channel can be identified leading to the sentinel node. Radioactivity counts of the lymphatic basin should be performed before and after excision after each node; the radioactivity counts of each excised node should be recorded after excision. Most practitioners excise all blue nodes and any node that has a count of at least 10% of the radioactivity of the "hottest" node.<sup>24</sup> All excised SLNs should be labeled in the operating suite because the blue dye and radioactivity will dissipate before the pathologic examination. No special handling for the sentinel node is required in regard to the radioactivity doses as the level of radiation exposure for surgeons and pathologists is very low. Handling of primary specimens (eg, lumpectomy specimens) involves higher exposures, and thus they should be stored until the dose rate and background rate equalize.<sup>25</sup>

#### MELANOMA AND OTHER SKIN CANCERS

The surgical management of regional lymph nodes in early-stage melanoma has been controversial for more than 100 years. Multiple retrospective single-institution studies have reported

a survival advantage of routine elective lymph node dissection (ELND) in patients without clinical evidence of regional lymph node metastases.<sup>26,27</sup> Prospective randomized trials, however, have failed to show an overall survival benefit for patients undergoing ELND instead of observation after wide local excision of the primary tumor.<sup>28-31</sup> These controversial reports, as well as the cost and morbidity associated with ELND, led Morton and colleagues at the John Wayne Cancer Institute to develop lymphatic mapping and SLNB.<sup>2</sup> This minimally invasive technique can identify patients with regional lymph node metastases who may benefit from a complete lymphadenectomy, while avoiding the morbidity of complete nodal dissection for patients without lymph node metastases. Furthermore, the small size of the nodal specimen allows microstaging with serial sectioning and IHC staining with S-100, Melan-A, and HMB-45.

SLNB was initially proposed for patients with an estimated risk of nodal metastases of greater than 10%. This included patients whose melanomas were at least 1.0 mm thick or had a Clark level IV depth of invasion.<sup>32</sup> The indications for the procedure have since been expanded to include patients with thinner melanomas, especially those with evidence of regression, ulceration, or positive deep margins.<sup>2</sup> Contraindications to SLNB include histologically confirmed clinically positive lymph nodes and previous extensive surgery at the primary site or in transit to the nodal basin, including prior rotational flaps, Z-plasties, or skin grafts that would make SLNB inaccurate.<sup>33</sup> SLNB should not be undertaken if the prognostic information will not change the clinical management, as may be the case for extreme elderly patients or those with more significant co-morbid conditions.

SLNB should be preceded by preoperative cutaneous lymphoscintigraphy. In the United States, this is primarily performed with  $^{99m}\text{Tc}$ -labeled sulfur colloid (SC) while other similar colloids are used in Europe and Australia. Briefly, on the day of surgery, 0.5 mCi of  $^{99m}\text{Tc}$ -SC is injected intradermally at the primary site or around the biopsy wound. Injections are given in four surrounding quadrants and the skin is gently massaged. Dynamic scans with a scintillation camera are performed to identify the drainage

pattern from the primary to the regional lymph nodes. The SLN is identified, and the overlying skin is marked to aid the surgeon for SLNB. The interval between injection of the tracer and the earliest identification of the SLN can vary from 1 to 30 minutes depending on the radiopharmaceutical and the distance between the primary and the nodal basin. By 4 hours after injection, the SLN in many cases can no longer be differentiated from adjacent non-SLNs.<sup>34</sup>

After lymphoscintigraphy, the patient is taken to the operating room (preferably within 2 to 6 hours). Once anesthesia is induced, 0.5 to 1.0 mL of isosulfan blue dye is injected intradermally using a 25-gauge needle at the site of the primary melanoma. If the primary site has already been excised, the dye is injected on either side of the biopsy scar. Approximately 5 to 10 minutes is necessary for the blue dye to reach the radioactive SLN. An incision is then made over the regional lymph node basin identified by lymphoscintigraphy and oriented so that a completion lymphadenectomy can be performed if needed. The skin flap closest to the primary melanoma is dissected so that the afferent lymphatics are observed as they and the SLN stain blue. With the assistance of a Geiger counter and blue dye, each SLN is identified and removed. Usually 1 to 3 (average 1.3) SLNs are identified and evaluated for metastases by permanent sectioning and staining with H&E and IHC. If metastases are identified, completion lymph node dissection should be performed as a second operative procedure.

To address this issue of pathologic confirmation of the sentinel node, carbon dye has been described by Haigh, et al.<sup>35</sup> as an adjunct in melanoma lymphatic mapping. This technique involves mixing carbon particles into the blue dye for injection for uptake into the lymph nodes. On pathologic examination these carbon particles can be seen in the lymph node, thus allowing for a positive identification of the sentinel node as well as the most likely site of intranodal tumor cells (Figure 4).<sup>11,35</sup> At this writing, this technique has not been widely adopted and there are no commercially available Food and Drug Administration–approved premixtures of blue dye and carbon dye.

In 1992, Morton and associates published their initial experience with SLNB.<sup>2,36</sup> They were able

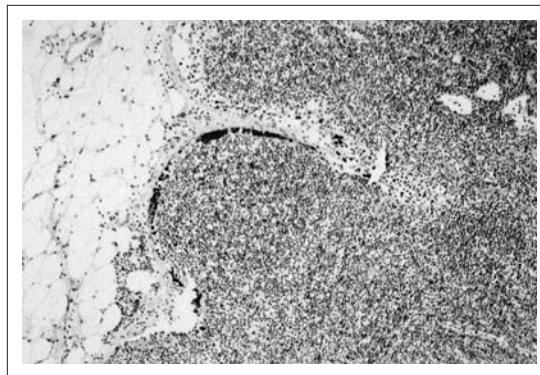


FIGURE 4 Carbon Dye Contained within a Lymph Node.

to successfully identify a blue-stained SLN in 194 (82%) of 237 regional lymph node basins. To evaluate the accuracy of the SLNB, all 223 patients underwent completion lymph node dissection (CLND) regardless of the pathology of the SLN. Of these specimens, 40 (21%) contained metastases in at least 1 lymph node. Only 2 of 194 (1%) of the basins had metastases in non-SLNs when the SLN was tumor free. The false-negative rate was thus 5% (2/40). These results are quite remarkable since most SLNs were identified without the aid of lymphoscintigraphy and the kinetics of blue dye was not fully understood. This study validated the accuracy of SLNB, which subsequently was confirmed by several other large major melanoma centers.<sup>37,38</sup>

While SLNB is a relatively difficult procedure to master, it has a steep learning curve. During their initial 58 cases, Morton's group identified only 81% of SLN; during the next 58 cases their success rate increased to 96% and now approaches 100%. The SLN was identified 97% of the time with an accuracy of 99% after 30 procedures were performed.<sup>38</sup> Recognizing that surgeon experience is directly related to successful identification of the SLN, the surgeon should monitor his or her false-negative rate through the learning phase by routinely performing CLND or performing the procedure with surgeons who have completed the learning phase.

SLNB has become widely adopted for regional lymph node staging in early-stage melanoma. The technique offers a valuable method to accurately evaluate the regional lymph node basin for both prognostication and selection of patients for adjuvant therapy. There is as yet no proven therapeutic benefit of this method. Information

regarding the therapeutic benefit must await the outcome of multicenter trials.

In 1994, the Multicenter Selective Lymphadenectomy Trial (MSLT-1) was begun by Morton and colleagues at the John Wayne Cancer Institute to determine the therapeutic benefit of SLNB and the accuracy of the technique on a worldwide basis. Patients with intermediate-thickness (1 to 4 mm) melanoma were prospectively randomly assigned to either wide local excision (WLE) of the primary and observation of the nodal basin or WLE and SLNB. CLND was performed only in regional lymph node basins that had tumor-positive SLN by H&E or IHC. A total of 2,001 patients were accrued, and final results of the trial are eagerly anticipated. To date, Morton has reported the accuracy and morbidity concluding that SLNB is associated with a 5% false-negative rate and a low (10%) minor complication rate.<sup>39</sup> Most recently Morton reported the third interim analysis (of five planned analyses) at the American Society of Clinical Oncology in 2005. To date, there is no difference in survival between the WLE and observation group versus the WLE and SLNB group. It is important to note that this is only an interim analysis, and two subsequent analyses to compare the survival between the two groups will follow. Also, patients in the SLNB group followed by CLND for metastases had a better disease-free survival compared with the WLE/observation group.<sup>40</sup> The organizers of the trial hope that on further analysis this study will demonstrate SLNB offers a therapeutic benefit in terms of survival compared with the wide excision and nodal observation. Regardless of the outcome, SLNB has become the standard approach for staging of regional lymph nodes. The same organizers have initiated MSLT II, a study to evaluate the therapeutic value of CLND in patients who have evidence of SN metastases (by conventional H&E histopathology, IHC, or RT-PCR) randomly assigned to CLND or observation of the nodal basin. The trial began accruing patients in January 2005, and should provide insight into the natural history of patients with a tumor-positive SN and the therapeutic benefit of CLND.

Several small, single-institution studies have reported the use of SLNB for nonmelanoma skin cancers, primarily for Merkel cell and squamous

cell skin cancers (SCCs).<sup>41-44</sup> Because these are skin cancers, the rationale for SLNB is similar to melanoma, namely, the ability to identify a limited lymph node sample that will be representative of the likelihood of lymphatic spread, and the avoidance of morbidity of a CLND in those in which the SLN is negative. Both cancers are known to spread through regional lymphatics—Merkel cell frequently and SCC seldomly—and thus, all patients with Merkel cell tumors should be considered for SLNB, while only those patients with SCC with risk factors for metastases (greater than 2 cm in diameter, immunosuppressed patients, or tumor invasion into deeper structures) may benefit from SLNB.<sup>44</sup> The combination technique of blue dye and radiotracer should be preferred because of the variability of lymphatic drainage. The accuracies and identification rates in these small studies have paralleled melanoma, suggesting a role for SLNB in non-melanoma skin cancer.<sup>41-44</sup> However, because of the small size and often short follow up of these case series, definitive conclusions regarding accuracy and identification rates in nonmelanoma skin cancer remain unclear. Nevertheless, it would be reasonable to offer the procedure as an alternative to ELND or observation in selected patients in a controlled setting.

#### BREAST CANCER

Breast cancer is the most common malignancy and the second most common cause of cancer-related deaths in women in Western countries. Since axillary lymph node status is the most important prognostic factor for recurrence and survival,<sup>45,46</sup> accurate staging of the axilla has been a key area of debate for many years. A complete axillary lymph node dissection (ALND) has been an integral part of breast cancer treatment since Halsted introduced the radical mastectomy.<sup>47</sup> Although ALND provides accurate staging and excellent local control, it carries a significant risk of morbidity, including lymphedema, decreased shoulder motion, and nerve paresthesias. The successful introduction of SLNB for melanoma by Morton and colleagues<sup>2</sup> led Giuliano and others<sup>48-50</sup> to adapt SLNB for breast cancer as an alternative to elective ALND for those with clinically negative lymph nodes. This

minimally invasive technique allowed node-negative patients to avoid the morbidity inherent in a wider dissection while providing staging information important in deciding on the need for adjuvant chemotherapy, as well as the extent of radiotherapy needed.

SLNB for primary breast cancer can be performed by a blue dye–only technique, a preoperative lymphoscintigraphy with intraoperative radiolocalization technique, or most commonly, the combination of both techniques. All these methods produce similar identification and false-negative rates when performed by experienced surgeons.<sup>51–54</sup> Several surgeons are proponents of the dye–only technique based on the similar identification rates with dye alone while avoiding the additional cost of lymphoscintigraphy. Other surgeons believe that radiolymphoscintigraphy is more accurate and identification of the SLN is quicker and easier with radiolymphoscintigraphic guidance. The method used should be based on institutional and surgeon experience and preference.

Multiple injection sites have been used to identify the sentinel node. Briefly, if radiocolloid is used, 12 to 16 mBq of <sup>99m</sup>Tc-labeled CS should be injected within 1 to 6 hours before surgery. At the time of surgery, 5 mL of isosulfan blue dye should be injected, with care taken not to inject the dye into the biopsy cavity if the injection is peritumoral. Subareolar injection has been validated in a number of large clinical trials and is particularly useful in multifocal or nonpalpable disease. A recent study by Povoski, et al.<sup>55</sup> compared intradermal, intraparenchymal, and subareolar injection routes for SLN identification and found the intradermal route to be superior. Once the isosulfan blue is injected, the breast should be massaged for 5 minutes to allow adequate flow of the dye into the lymphatics. After massage, an incision should be made beneath the axillary hair line at the location of the hot spot if radioisotope is used. The clavipectoral fascia should be entered, and with blue dye and/or assistance of a Geiger counter, the SLN is identified and removed and evaluated for metastases by permanent sectioning staining with serial sections using routine H&E staining. If metastases are identified, ALND is performed as a second operation.

The accuracy of SLNB is not affected by the type of diagnostic biopsy (fine-needle aspiration, core, or excisional biopsy), the interval between initial biopsy and definitive surgery, the location of the primary breast tumor, or type of definitive surgery (breast conservation or mastectomy). Initially SLNB was limited to patients with small tumors because clinicians believed that tumor embolization from bulkier tumors might obstruct and alter lymphatic drainage, leading to a falsely negative SLN. However, since then several studies have demonstrated the high identification rates and low false-negative rates for SLNB in large tumors as well.<sup>56–58</sup>

The role of SLNB in patients believed to have only ductal carcinoma in situ (DCIS) is still controversial, since by definition, DCIS does not spread to lymph nodes. The role of SLNB is primarily to identify those patients in whom occult invasive disease may have been undetected—particularly when needle biopsy was used for preoperative diagnosis. Although the indications vary by surgeon, many perform SLNB for large lesions, high-grade DCIS, or a mass associated with DCIS.<sup>59</sup> The other common indication is for patients with DCIS undergoing mastectomy, as SLNB would be inaccurate after mastectomy forcing an ALND if invasive disease was subsequently found.

The role of SLNB after neoadjuvant chemotherapy is controversial. Although some authors<sup>60</sup> have indicated high concordance rates of SLNB and ALND after chemotherapy, the National Surgical Adjuvant Breast and Bowel Project Protocol B-27 trial reported a false-negative rate of 11%, substantially higher than routine SLNB.<sup>61</sup> Less is also known regarding the prognosis of patients who do not undergo ALND after conversion from node positive to node negative by neoadjuvant therapy. Accordingly, the American Society of Clinical Oncology 2005 practice guidelines concluded that there are insufficient data to recommend SLNB for patients receiving preoperative systemic chemotherapy.<sup>62</sup> Accordingly, SLNB should be primarily performed in the setting of a protocol after neoadjuvant chemotherapy. Currently, most surgeons perform SLNB before neoadjuvant chemotherapy, which has been established to be accurate<sup>63</sup> except in inflammatory breast cancer.

The AJCC recently changed its staging of micrometastases.<sup>64</sup> Tumor deposits smaller than 0.2 mm are considered isolated tumor cells and pN0, whereas deposits between 0.2 and 2 mm are pN1<sub>mi</sub>. The isolated tumor cells (pN0) are not considered positive with this new change, and ALND should not be performed. The significance of isolated tumor cells and micrometastatic disease is unclear, particularly in the setting of effective chemotherapy, and is the subject of much debate and ongoing clinical trials, such as the International Breast Cancer Study Group 23-01 trial<sup>65</sup> and the recently closed ACoS Oncology Group Z0010 trial.<sup>66</sup> Following excision, the SLN is evaluated with routine serial H&E-stained sections. Unlike melanoma, the routine use of IHC staining is not recommended since the significance of IHC-only positive metastases is unclear.

Some institutions perform intraoperative analysis of the SLN with either frozen section or touch preparation. The reliable identification of SLN metastases would allow completion lymphadenectomy to be performed at the time of the initial surgery, avoiding a second surgery. A recent study by Brogi, et al.<sup>67</sup> compared the results of frozen section, touch preparation, and cytologic smear for intraoperative identification of SLN metastases. The study reported similar results for each of the 3 methods with sensitivities compared with permanent sectioning of 59%, 57%, and 59%, respectively. Not surprisingly, the sensitivities were 96%, 93%, and 93%, respectively, for macrometastases. Because of the poor sensitivity of intraoperative evaluation and the possibility of missing small metastases from destruction of tissue during intraoperative evaluation, several institutions, including our own, prefer to perform permanent sectioning followed by ALND for positive SLNs and primarily reserve intraoperative evaluation in patients who have clinically suspicious SLNs at the time of surgery.

Most large studies report SLN identification rates of greater than 90% and accuracy greater than 95%.<sup>51-53</sup> Several studies have evaluated the number of procedures a surgeon must perform so that they can successfully and accurately identify the SLN. Cox, et al.<sup>68</sup> at the Moffitt Cancer Center evaluated their own experience using a combination technique with blue dye and radio-

colloid and found that 22 cases needed to be performed to achieve failure rates less than 10% and 54 cases to achieve rates lower than 5%. Furthermore, surgeons need to perform six or more procedures per month to continue to perform accurately.<sup>69</sup> A multicenter trial of both academic and community surgeons revealed that after 30 cases, identification and false-negative rates were 90% and 4.3%, respectively.<sup>70</sup>

There have been two major prospective randomized trials evaluating the morbidity associated with SLNB in breast cancer. Veronesi, et al.<sup>71</sup> compared ALND to SLNB and found that patients with SLNB had better arm mobility and aesthetic appearance, as well as less pain, paresthesias, and lymphedema. Similarly, the ACoS Oncology Group Z0010 trial reported the low rate of complication following SLNB.<sup>4</sup> Anaphylaxis to blue dye occurred in 0.1% of subjects. Other complications include wound infection (1.0%), axillary seroma (7.1%), and hematoma (1.4%). At 6 months, 8.6% of patients reported paresthesias, 3.8% decreased upper extremity range of motion, and 6.9% lymphedema. These figures are all lower or not substantially different from historical figures for ALND. This improvement in morbidity is most likely due to the lesser amount of dissection and disturbance of the lymphatic system. Thus, while not without risks, these studies confirm that SLNB is a safe alternative to ALND with early-stage breast cancer.

SLNB for early-stage breast cancer has become widely adopted for regional lymph node staging and is indicated in all patients with clinical Stage I and II, node-negative breast cancer. The technique has been validated with large-scale prospective trials to accurately stage the axilla in experienced hands and is the standard of care for those with adequate experience.

#### COLORECTAL CANCER

The accuracy of lymph node staging for colorectal cancer is related to the number of lymph nodes examined; increasing the number of lymph nodes examined correlates with improved survival and decreased recurrence in node negative patients.<sup>72,73</sup> A popular explanation for this phenomenon is that the examining of more lymph



nodes increases the likelihood of identifying patients with small nodal metastases. This so-called stage migration effect improves survival by more efficient selection of those patients requiring adjuvant therapy, while more accurately staging those thought to be without nodal metastasis. Adjuvant therapy for node-positive colon cancers has yielded survival improvements, particularly with combination regimens such as Fluorouracil, leucovorin, and oxaliplatin (FOLFOX).<sup>74</sup> Thus, the failure to properly stage a node-positive patient can have a dramatic effect on survival. On the other hand, current guidelines suggest avoiding adjuvant therapy in patients with Stage II disease,<sup>75</sup> although many assume that, based on the trends seen in those studies, adjuvant therapy of patients with Stage II disease may be justified.<sup>76</sup> Rectal cancer, in contrast, is often treated with neoadjuvant chemoradiation therapy as well as adjuvant chemotherapy, even in Stage II.

The use of sentinel node mapping in colon cancer is probably the best studied of the nonbreast, nonmelanoma tumors. Disease in node-negative patients with colon cancer will recur up to 30% of the time after curative resection. Because the level of lymphadenectomy in colon resection is not believed to pose any excess morbidity, the rationale for SLNB rests primarily on the identification of nodes for ultrastaging to identify which patients might benefit from adjuvant therapy.

The technique for colon cancer mapping involves injection of the dye either percutaneously or via a colonoscope for laparoscopic colectomy, or after minimal mobilization when performed via open laparotomy. After resectability of the primary tumor has been determined, 0.5 to 1 mL of isosulfan blue dye is injected subserosally around the periphery of the tumor (Figure 5). A radiocolloid (1 mCi of <sup>99m</sup>Tc) may also be used as an adjunct to facilitate the detection of the sentinel node. Typically, the dye reaches the sentinel node within 30 to 60 seconds via the lymphatics, so when performed laparoscopically, the colonoscopy must be performed after the laparoscopic examination of the abdomen. Occasionally gentle dissection of the mesentery is needed to trace the lymphatic path to the blue-stained SLN (Figure 6). If a radiotracer was used, a gamma probe may help direct this dissection. Since the blue dye

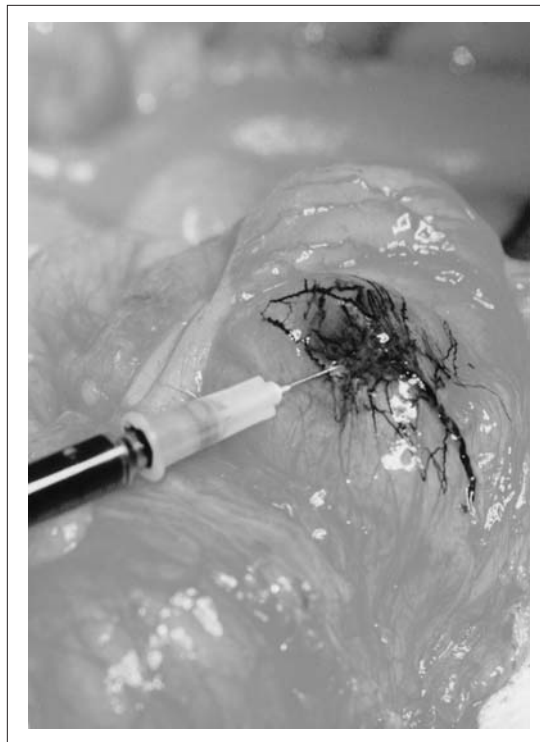

FIGURE 5 Injection of Blue Dye for a Colon Cancer Sentinel Node Biopsy.

washes out with time and with further pathologic processing, each stained node is marked with sutures or clips. After this marking, all blue nodes should be included in the standard colectomy. The specimen is submitted for a focused pathologic examination of the SLNs, as well as a standard evaluation of all other lymph nodes. If aberrant drainage is noted, the resection boundaries are extended to include the mesenteric areas and blood supply.

As an alternate technique, ex vivo SLNB was first described by Wong, et al.<sup>77</sup> and has proven to be successful both as a primary lymphatic mapping procedure and as a salvage technique when in vivo mapping fails.<sup>78,79</sup> In the operating room, the colectomy specimen is immediately taken to a side table and 1 to 2 mL of isosulfan blue dye is injected subserosally around the tumor using a tuberculin syringe. The dye can be visualized as it progresses from the primary site along the lymphatic channels to the SLN(s) within the mesentery (Figure 7). Again, each SLN is marked with sutures, and the specimen is submitted for pathologic review, including a focused examination of the SLNs.

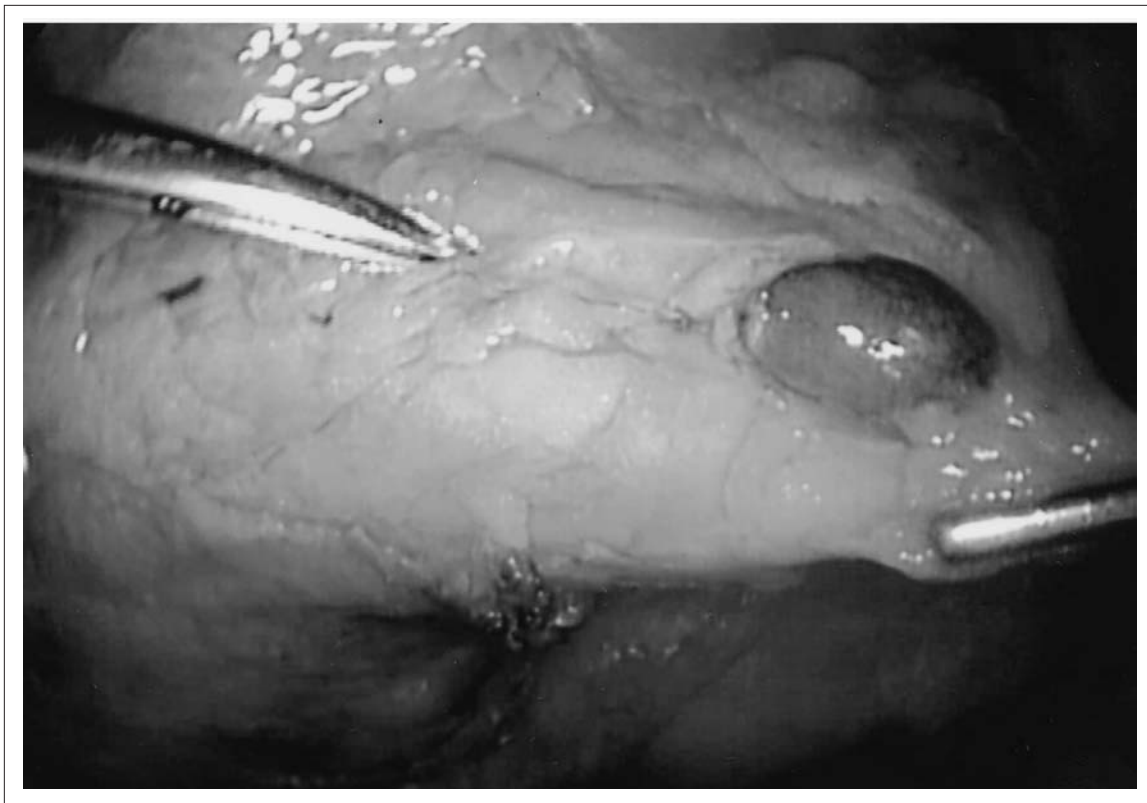


FIGURE 6 Blue-dyed Node Seen Laparoscopically during Colon Cancer Resection.

Initial reports of SLNB for colon cancer had high identification and accuracy rates ranging from 70%<sup>80</sup> to 100%.<sup>81</sup> As the technique has developed, most investigators are now able to routinely achieve over 90% success in identifying the sentinel node and accuracy rates of approximately 90%.<sup>82</sup> One notable exception is the Cancer and Leukemia Group B (CALGB) trial reported by Bertagnolli, et al.,<sup>83</sup> which found that despite a 92% success rate in localizing a sentinel node, accuracy was only 80% and there was a high false-negative rate of 54% when H&E analysis was used alone. A subsequent analysis of the same patients by IHC increased the sensitivity rate to as high as 88% depending on the definition used for a tumor-positive sentinel node.<sup>84</sup> In addition, its relatively small number of patients (91) enrolled over a large number of surgeons (25) and centers (13) may have affected its success. This contrasts with a larger multi-center series reflecting those with more extensive experience that demonstrated an accuracy rates of 95% with an 11% false-negative rate over 408 colon cancer patients and an accuracy rate

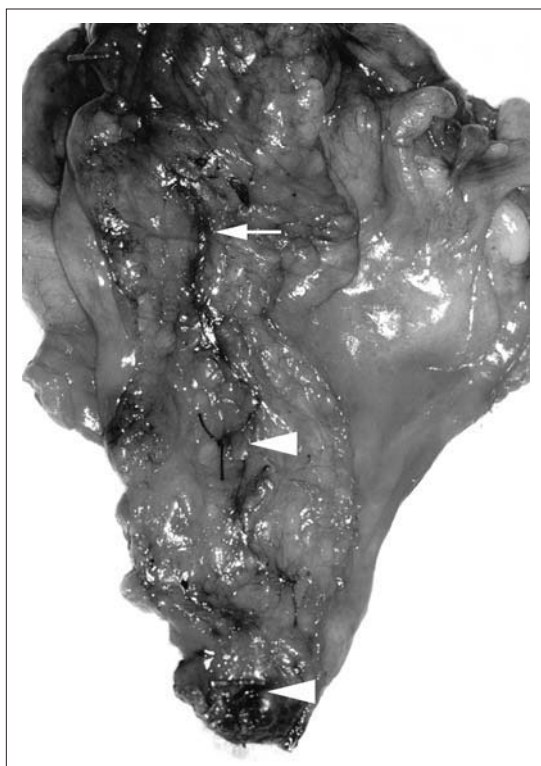


FIGURE 7 Lymphatic Channel Seen Tracking to a Blue-dyed Node in a Colon Cancer Specimen.

of 98% and a false-negative rate of 7% over 92 patients with rectal cancer.<sup>85</sup> All surgeons in this series had performed more than 30 colon cancer SLNBs compared with those in the CALGB trial, who were only required to be proficient in the SLNB for breast cancer and melanoma. Preliminary results from another prospective multicenter trial headed by the John Wayne Cancer Institute recently reported a 100% identification rate, with an 88% sensitivity.<sup>86</sup> Upstaging in this trial by focused analysis was 24%, thus indicating its importance when analyzing sentinel nodes. This upstaging may represent an increased risk of recurrence, potentially indicating the need for chemotherapy that may not have been previously apparent.

Rectal cancer SLNB is performed in a similar fashion to colon cancer SLNB. Difficulties can arise from the rectal cancer location being inaccessible without disrupting the mesocolon if the lesion is extraperitoneal. While the ability to find sentinel nodes has been reported to be as high as 91%,<sup>85</sup> concerns have been expressed about the use of preoperative chemoradiation. Braat, et al.<sup>87</sup> reported a sensitivity of 40% in rectal cancer treated with preoperative radiotherapy. This contrasted with the same authors' sensitivity rate of 90% for colon cancers.

Overall, SLNB continues to be a promising technique for the evaluation of the colorectal nodal basins, but more work is necessary to standardize the procedure and determine the minimum number of cases needed for proficiency such that accuracy can be ensured across surgeons and pathologists. Rectal carcinomas should be approached with more caution, and in no cases should a standard mesenteric resection be forgone in favor of an SLNB alone.

#### GASTRIC CANCER

Lymphatic metastasis is the most important prognostic factor for survival in gastric cancer. Removal of the tumor with an extended lymphadenectomy (D2 resection) is now considered the preferred level of dissection required for optimizing long-term survival if lymph node metastasis is present. However, current preoperative imaging studies have poor sensitivity for the assessment of nodal status. The depth/extent

of invasion is also inadequate for the prediction of nodal metastasis since T1 gastric cancers have a 15% rate of nodal metastasis overall, and even tumors that involve mucosa only (T1a) have a 2% risk of nodal metastasis.<sup>88</sup> Proof of concepts in the use of the sentinel node technique in gastric cancer has been published from as early as 2000.<sup>89</sup>

SLNB for gastric cancer was described as early as 2000 by our group at the John Wayne Cancer Institute. SLNB is undertaken to improve staging and guide the extent of resection. Because up to 38% of gastric cancers have their first site of metastasis in other than the perigastric nodal area,<sup>90</sup> SLNB can better identify the most likely site of nodal metastasis to direct the extent of both nodal dissection and gastric resection. Since a return to the operating room for further lymph node dissection is impractical, the use of intraoperative frozen section analysis to determine SLN status may be able to simplify operations and avoid potential morbidities while preserving the reported survival benefits of extended lymphadenectomies.<sup>91-93</sup> Because adjuvant chemotherapy after curative resection is typically reserved for those at high risk of recurrence,<sup>94</sup> SLNB may also improve the selection of patients for adjuvant therapy.

The choice of blue dye or radiocolloid is based on surgeon preference, although a combined technique has been reported to reduce technical errors.<sup>95</sup> For those using <sup>99m</sup>Tc radiocolloid, the typical technique is injection via an esophagogastroduodenoscopy (EGD) of approximately 0.5 mL of radiocolloid in four quadrants surrounding the tumor corresponding to an approximately 150-MBq dose.<sup>96</sup> Injection can be performed between 2 hours and 20 hours. <sup>99m</sup>Tc-tin colloid has been reported as the optimal tracer.<sup>95</sup> For those preferring blue dye, 0.5 to 1 mL of isosulfan blue dye or indocyanine green<sup>97</sup> is injected intraoperatively, after minimal dissection to locate the tumor. SLNs are identified via visual inspection and/or by use of the gamma probe.

Reported rates by single institutions of SLN identification range from 94% to 100%, and reported sensitivity of SLN assessment exceeds 85%.<sup>97,98</sup> Prospective multicenter trials are underway internationally in both Japan and Europe

and should provide answers regarding its usefulness in more general practice.

#### ESOPHAGEAL CANCER

SLNB for esophageal cancer is in the earliest stages of development. Small, single-institution studies have been primarily performed in Japan, where radical extended lymph node dissection is undertaken for esophageal cancer.<sup>99,100</sup> Although patients have a better prognosis after radical surgery, many sustain significant morbidity and long-term postoperative problems.<sup>101</sup> SLNB offers the ability to identify patients with lymph node metastases who would benefit from extended lymphadenectomy. In addition, pathologic ultrastaging of the lymph nodes identified as SLNs can determine which patients should receive adjuvant therapy.

Blue dye is not generally feasible for mapping esophageal cancer since real-time observation of the dye would require mobilization of the esophagus, which would destroy the normal lymphatic flow itself.<sup>102</sup> The lymphatic drainage is variable, draining to cervical, thoracic, and/or abdominal compartments. Since blue dye is not feasible, preoperative endoscopy is used to inject 2.0 mL <sup>99m</sup>Tc-tin colloid in 4 quadrants surrounding the tumor. Lymphoscintigraphy performed 3 hours after injection can be very useful in identifying the SLN despite the variable lymphatic drainage. However, preoperative imaging often can be difficult to interpret due to the close proximity of the primary tumor to the SLN.<sup>103</sup>

Feasibility studies report that SLNB can predict the status of the lymphatic basin in 69% to 100% of patients. These small studies (6 to 40 patients) evaluated heterogeneous populations with different stages of disease.<sup>99,100,104</sup> SLNB for esophageal cancer, while promising, continues to be in its infancy and thus should be performed on protocol.

#### HEAD AND NECK TUMORS

The traditional management of early oral and oropharyngeal carcinoma with a cN0 neck often results in nontherapeutic neck dissection with suboptimal staging. Since radical neck dissection

can result in significant morbidity, limited neck dissections have been performed in selected cases. In these selected cases, negative histologic results of level I lymph nodes have been used to predict the nodal status of the remaining neck (level II to VI). Because selective nodal analysis has been used for years with acceptable negative predictive values, there is high interest in substituting SLN status as a predictive marker.<sup>105-110</sup> SLNB for head and neck cancers can decrease morbidity by further limiting the neck dissection. Because most patients do not have lymphatic metastases, SLNB would allow them to avoid completion neck dissections. Focused pathologic examination of the SLN(s) may also provide for upstaging of patients who might otherwise have had missed metastases.

The most important technical consideration in performing SLNB in head and neck cancer is a mastery of the complex lymphatic drainage of this region. The minimal requirements for head and neck lymphatic mapping include the use of a radiotracer, lymphoscintigraphy, and a handheld gamma probe; additional tracers are used at some centers (eg, isosulfan blue).<sup>111</sup> There is no standard amount of radioactive tracer (SC) used to detect an SLN; a recent review of 19 studies reported dose variations from 0.037 to 111MBq.<sup>112</sup> Since this type of radio-guided surgery is an evolving technique, it requires careful coordination among the surgeon, nuclear medicine physician, and pathologist. Before the procedure the SLN should be visualized via lymphoscintigraphy, and the injection site should be critically evaluated for the proximity (peritumoral) to the primary lesion.

Several trials have shown SLNB improves staging of head and neck squamous cell carcinoma,<sup>113-115</sup> but most are validation studies to assess feasibility and accuracy and must be interpreted cautiously in light of the learning curve for this procedure.<sup>115</sup> Since the impact of micrometastatic disease is still controversial, the current benefit of SLNB lies in its ability to reduce the need for lymph node dissection by accurate prediction of the tumor status of the remaining nodal basin. Although individual experience varies, a recent meta-analysis by Paleri, et al.<sup>112</sup> reported a 97.7% SLN identification rate. The negative predictive value of SLNB is 96%.<sup>105-108, 116-120</sup>

The use of SLNB upstages approximately 29% of patients with an approximately 4% false-negative rate.<sup>111</sup>

The ACoS and the National Cancer Institute have begun a multicenter diagnostic trial (ACOSOG-Z0360) to study the effectiveness of SLNB in early-stage cancer of the mouth. The trial is designed to determine whether an SLN that is H&E negative for tumor accurately predicts the absence of tumor in other cervical lymph nodes in patients with Stage I or II squamous cell carcinoma of the oral cavity. The trial will also determine the extent and pattern of disease spread in the nodal bed and obtain data on the use of IHC to assess nodes in these patients. Currently, SLNB in this setting should be performed under study protocol only. We encourage patients to enroll in multicenter clinical trials to answer important questions regarding the clinical utility of this technique in head and neck squamous cell carcinoma.

#### THYROID CARCINOMA

Occult lymph node metastasis of thyroid cancer is common, but since the prognostic significance of nodal metastases in the cN0 neck of patients with differentiated thyroid carcinoma is unclear, nodal sampling/assessment is controversial. However, in certain high-risk patients, identification of nodal metastases can change the stage of disease, leading to altered surgical management, as well as possibly affecting the role of radioiodine ablative management.

The AJCC defines patients 45 years and older with differentiated thyroid cancer as high risk.<sup>7</sup> In these patients, stage is affected by the presence of lymphatic metastases even in the face of an otherwise favorable T1 primary tumor. For example, metastatic disease within the regional lymph nodes in a cN0 neck of a high-risk patient is staged as III or higher. Metastases identified in the cervical and/or superior mediastinal lymph nodes correspond to Stage IVA disease or higher in the high-risk patient despite having a favorable primary tumor. Although discrepancy exists regarding the effect lymphatic metastases on survival,<sup>121,122</sup> several studies have shown that lymphatic metastases denote disease progression.<sup>123,124</sup> The staging system for medullary thyroid

carcinoma is similar to high-risk differentiated thyroid carcinoma. In this setting, the presence of lymphatic metastases also denotes more advanced disease that can often alter management. For this reason, several centers of excellence perform “blind” central (level VI) and superior mediastinal (level VII) neck dissection to excise potential metastatic disease in patients with cN0 high-risk differentiated and medullary thyroid carcinoma. This type of dissection often includes several pretracheal, paratracheal, and prelaryngeal/Delphian lymph nodes. Although this is the most common lymphatic drainage pattern of thyroid cancer, lymphatic mapping has shown that there are exceptions to typical drainage patterns in thyroid carcinoma.<sup>125,126</sup>

Identification of lymphatic metastases is common after routine/“blind” central neck dissections, and when recurrences do occur, they are most often in the regional nodal basin.<sup>127</sup> Based on this recurrence pattern, we believe that the greatest benefit from SLNB in thyroid carcinoma may lie in the identification of occult disease outside the central neck (level VII). Although the total number of patients who would benefit from this approach may be small, it is a reasonable and more logical approach when compared with prophylactic lymphatic dissection. Limiting lymphatic dissection when the SLN is not involved could also potentially limit the morbidity of hypoparathyroidism and recurrent laryngeal nerve injury that has been reported with lymphatic resection.<sup>128</sup>

Most published studies have been feasibility studies showing the technique can be performed safely and can predict the disease status in the remaining regional nodal basin with high accuracy in most patients (80% to 100%).<sup>125,126,129–136</sup> At our center, the SLN can be identified in more than 90% of patients, which is comparable to published reports (66% to 100%).<sup>129–136</sup> The SLN can be identified using isosulfan blue and/or <sup>99m</sup>Tc-labeled colloid albumin. At our institution <sup>99m</sup>Tc-labeled colloid albumin is not used due to the “shine-through” phenomenon in which the close proximity of the primary lesion results in high radiation counts throughout the entire lymphatic basin, obscuring the ability to locate the lymphatic drainage. We carefully expose the thyroid gland, ensuring minimal lymphatic

disruption by using sharp dissection with meticulous hemostasis. Our preferred method is to identify the suspicious thyroid nodule before vessel ligation or medial dislocation of the gland. One to 2 mL of isosulfan blue is then injected into the thyroid nodule using a tuberculin syringe. The technique includes injection of the nodule itself because the remaining normal lobe of the gland can be quite small when compared with the nodule, and a peritumoral injection technique may not be accurate or possible. Additionally, the gland can often have several benign nodules located near the suspicious nodule, and a peritumoral injection could affect the lymphatic mapping process. Usually within seconds (range up to 2 minutes) the blue lymphatic channels appear and can be traced to the SLN, which is removed and sent to pathology for intraoperative analysis. This technique does not affect the histology of the thyroid nodule, and the blue dye is essentially undetectable after processing. If no metastases are identified within the SLN, no further lymphatic dissection is performed, but if the SLN contains metastases, the regional nodal basin is removed. If intraoperative pathologic analysis is negative, but the final pathology reveals metastasis, the volume of disease is uniformly low. This low-volume disease is most commonly identified in well-differentiated radio-sensitive tumors, making the overall benefit of a second operation for regional nodal dissection negligible in most cases.

Although this procedure is not considered the standard of care, SLNB for thyroid malignancy can assist in the identification of occult lymphatic metastases. We believe the technique is safe and can provide additional information that can affect clinical decision making in treating both papillary and follicular lesions of the thyroid. The technique needs to be validated in each individual center for accuracy, and a risk/benefit discussion needs to be completed before this, as in any other, diagnostic tests/procedures.

#### LUNG CANCER

Non-small cell lung cancer (NSCLC) represents the leading cause of cancer deaths within the United States and is among the leading causes of cancer death in many other countries as well.

As in melanoma and breast cancer, lymphatic metastasis has clear prognostic value.<sup>137</sup> Although surgical dissection of regional lymphatics improves treatment results in patients with mediastinal lymphatic metastases, its therapeutic effect has been questioned.<sup>138-140</sup> As with other solid tumors, regional lymphadenectomy is not therapeutic in patients without lymph node metastases and is associated with some potential morbidity from further dissection into the mediastinum (eg, chylothorax). Early-stage NSCLC has favorable survival rates, but there are high rates of recurrence for patients with T1 N0 disease (20% to 50%). Additionally, reported 5-year survival rates have wide ranges. Considering the extensive lymphatic drainage of the lung, this high level of recurrence may be a result of incomplete or inaccurate lymphadenectomy. Intraoperative evidence of the tumor lymphatic drainage pattern could improve the selection of the lymphatic basin for dissection and thus limit the number of unnecessary mediastinal lymphadenectomies and related morbidity. Finally, identification of the SLN would allow pathologists to perform a focused pathologic examination to identify micrometastases, which reportedly have a similarly poor prognosis as macrometastases (N1) in some studies.<sup>141,142</sup>

Little, et al. described a technique for identifying SLN in NSCLC in 1999.<sup>143</sup> In this initial report, isosulfan blue dye (blue dye) was peritumorally injected; however, the SLN identification rate was only 46%. More recent reports have used several different methods of injection and different tracers in an attempt to establish the feasibility of SLNB for clinical use. Methods for tracer injection include intraoperative, CT-guided preoperative, and transbronchoscopic techniques. The tracers used include isosulfan blue dye alone, <sup>99</sup>Tc-sulfur or -tin colloid alone or in combination with blue dye, indocyanine green, <sup>99</sup>Tc-nanocolloid, and magnetite.<sup>144-155</sup> In 2003, two studies identified the SLN in 95% or more of cases by using a combination of preoperative and intraoperative and/or transbronchoscopic injection of <sup>99</sup>Tc-nanocolloid.<sup>144,146</sup> Using the combined blue dye and radiotracer approach, our group reported in 2004, a 100% SLN identification rate among 39 patients with primary NSCLC. One case involving a patient

who received neoadjuvant chemotherapy was deemed a false negative, although that patient did have evidence of tumor regression in the SLN.<sup>147</sup>

Although the procedure is feasible and safe, SLNB in NSCLC remains investigational at this time but can be performed well by experienced surgeons. Prospective validation in larger multicenter trials may help clarify the route and timing of injection, the optimal tracer or combination of tracers to be used, and the dose of the tracers.

#### OTHER SITES

Although outside the scope of this article, sentinel node technology has also been used in both gynecologic and urologic applications. For gynecology, successful application of sentinel node techniques in endometrial,<sup>156</sup> cervical,<sup>157</sup> and vulvar cancers<sup>158</sup> have been described. Urologic applications have included prostate<sup>159</sup> and bladder<sup>160</sup> cancers. As yet, sentinel node biopsy has not gained wide acceptance in the gynecologic and urologic communities and is still primarily done as a part of an experimental protocol.

#### FUTURE IMPLICATIONS

SLNB has become a standard diagnostic component in breast cancer and melanoma. Its use for these and other tumors reflects its promise in virtually any tumor that spreads primarily through

lymphatic channels. Although evidence of a definitive survival benefit awaits results of ongoing multicenter trials, it is clear that SLNB can improve the accuracy of staging of tumors, while often eliminating the need for CLND with its attendant morbidity. Lymphoscintigraphic identification of lymph node drainage basins can also alter surgical procedures by showing in-transit metastases and aberrant drainage patterns, thus improving the potential efficacy of operations and improving the diagnostic yield of staging operations. To the extent that micrometastatic disease becomes an important consideration in the prognosis of patients, SLNB remains an efficient way of identifying a subset of lymph nodes that can be staged in an intensive manner. This improved staging may allow clinicians to better stratify patients who might benefit from adjuvant therapy after a “curative” resection that renders patients without evident disease. Thus, while SLNB may not have improved their survival alone, when combined with other modalities it offers the possibility of focusing the benefits of other therapies on those who can most benefit, while allowing those with minimal benefit to avoid the morbidity of further operations or chemotherapy.

In the future, molecular assays of markers of the primary tumor or in circulating tumor cells or DNA may provide similar information to the SLN. However, until that time, SLNB remains an accurate, minimally invasive method for identifying lymphatic metastasis from solid tumors.

#### REFERENCES

- Morton D, Cagle L, Wong J, et al. Intraoperative lymphatic mapping and selective lymphadenectomy: technical details of a new procedure for clinical stage I melanoma. Presented at: Annual Meeting of the Society Surgical Oncology; May 1990, Washington, DC.
- Morton DL, Wen DR, Wong JH, et al. Technical details of intraoperative lymphatic mapping for early stage melanoma. *Arch Surg* 1992;127:392–399.
- Giuliano AE, Kirgan DM, Guenther JM, Morton DL. Lymphatic mapping and sentinel lymphadenectomy for breast cancer. *Ann Surg* 1994;220:391–398.
- Wilke LG, McCall LM, Posther KE, et al. Surgical complications associated with sentinel lymph node biopsy: results from a prospective international cooperative trial. *Ann Surg Oncol* 2006; 13:491–500.
- Schrenk P, Rieger R, Shamiyeh A, Wayand W. Morbidity following sentinel lymph node biopsy versus axillary lymph node dissection for patients with breast carcinoma. *Cancer* 2000;88:608–614.
- Purushotham AD, Upponi S, Klevesath MB, et al. Morbidity after sentinel lymph node biopsy in primary breast cancer: results from a randomized controlled trial. *J Clin Oncol* 2005;23: 4312–4321.
- Greene FL, Page DL, Fleming ID, et al. *AJCC Cancer Staging Manual*. 6th ed. New York: Springer-Verlag; 2002.
- Essner R, Cochran AJ. Sentinel node biopsy: not only a staging tool? *Recent Results Cancer Res* 2002;160:133–148.
- Xu X, Roberts SA, Pasha TL, et al. Undesirable cytokeratin immunoreactivity of native nonepithelial cells in sentinel lymph nodes from patients with breast carcinoma. *Arch Pathol Lab Med* 2000;124: 1310–1313.
- Bostick PJ, Morton DL, Turner RR, et al. Prognostic significance of occult metastases detected by sentinel lymphadenectomy and reverse transcriptase-polymerase chain reaction in early-stage melanoma patients. *J Clin Oncol* 1999;17: 3238–3244.
- Morton DL, Hoon DS, Cochran AJ, et al. Lymphatic mapping and sentinel lymphadenectomy for early-stage melanoma: therapeutic utility and implications of nodal microanatomy and molecular staging for improving the accuracy of detection of nodal micrometastases. *Ann Surg* 2003; 238:538–549.
- Lockett MA, Baron PL, O'Brien PH, et al. Detection of occult breast cancer micrometastases in axillary lymph nodes using a multimarker reverse transcriptase-polymerase chain reaction panel. *J Am Coll Surg* 1998;187:9–16.
- Noguchi S, Aihara T, Nakamori S, et al. The detection of breast carcinoma micrometastases in axillary lymph nodes by means of reverse transcriptase-polymerase chain reaction. *Cancer* 1994;74:1595–1600.
- Aihara T, Fujiwara Y, Ooka M, et al. Mammaglobin B as a novel marker for detection of

breast cancer micrometastases in axillary lymph nodes by reverse transcription-polymerase chain reaction. *Breast Cancer Res Treat* 1999;58:137-140.

15. Wascher RA, Bostick PJ, Huynh KT, et al. Detection of the MAGE-A3 in breast cancer patients' sentinel nodes. *Br J Cancer* 2001;85:1340-1346.

16. Bilchik AJ, Saha S, Wiese D, et al. Molecular staging of early colon cancer and its impact on staging. *Ann Surg Oncol* 2000;7:120-124.

17. Kammula US, Ghossein R, Bhattacharya S, Coit DG. Serial follow-up and the prognostic significance of reverse transcriptase-polymerase chain reaction-staged sentinel lymph nodes from melanoma patients. *J Clin Oncol* 2004;22:3989-3996.

18. Leong SP, Donegan E, Heffernon W, et al. Adverse reactions to isosulfan blue during selective sentinel lymph node dissection in melanoma. *Ann Surg Oncol* 2000;7:361-366.

19. Blessing WD, Stolier AJ, Teng SC, et al. A comparison of methylene blue and lymphazurin in breast cancer sentinel node mapping. *Am J Surg* 2002;184:341-345.

20. Simmons R, Thevarajah S, Brennan MB, et al. Methylene blue dye as an alternative to isosulfan blue dye for sentinel lymph node localization. *Ann Surg Oncol* 2003;10:242-247.

21. Gershenwald JE, Tseng CH, Thompson W, et al. Improved sentinel lymph node localization in patients with primary melanoma with the use of radiolabelled colloid. *Surgery* 1998;24:203-210.

22. Krag DN, Meijer SJ, Weaver DL, et al. Minimal access surgery for staging of malignant melanoma. *Arch Surg* 1994;130:654-658.

23. Essner R. The role of lymphoscintigraphy and sentinel node mapping in assessing patient risk in melanoma. *Semin Oncol* 1997;24:S8-S10.

24. McMasters KM, Reintgen DS, Ross MI, et al. Sentinel lymph node biopsy for melanoma: how many radioactive nodes should be removed? *Ann Surg Oncol* 2001;8:192-197.

25. Stratmann SL, McCarty TM, Kuhn JA. Radiation safety with breast sentinel node biopsy. *Am J Surg* 1999;178:454-457.

26. Balch CM, Soong SJ, Murad TM, et al. A multifactorial analysis of melanoma. II. Prognostic factors in patients with stage I (localized) melanoma. *Surgery* 1979;86:343-351.

27. Milton GW, Shaw HM, McCarthy WH, et al. Prophylactic lymph node dissection in clinical stage I cutaneous malignant melanoma: results of surgical treatment in 1319 patients. *Br J Surg* 1982;69:108-111.

28. Sim FH, Taylor WF, Ivins JC, et al. A prospective randomized study of the efficacy of routine elective lymphadenectomy in management of malignant melanoma. Preliminary results. *Cancer* 1978;41:948-956.

29. Veronesi U, Adamus J, Bandiera DC, et al. Inefficacy of immediate node dissection in stage I melanoma of the limbs. *N Engl J Med* 1977;297:627-630.

30. Veronesi U, Adamus J, Bandiera DC, et al. Delayed regional lymph node dissection in stage I melanoma of the skin of the lower extremities. *Cancer* 1982;49:2420-2430.

31. Balch CM, Soong SJ, Bartolucci AA, et al. Efficacy of an elective regional lymph node dissection of 1 to 4 mm thick melanomas for patients 60 years of age and younger. *Ann Surg* 1996;224:255-266.

32. Balch CM, Soong SJ, Milton GW, et al. A comparison of prognostic factors and surgical results in 1,786 patients with localized (stage I) melanoma treated in Alabama, USA, and New South Wales, Australia. *Ann Surg* 1982;196:677-684.

33. Kelley MC, Ollila DW, Morton DL. Lymphatic mapping and sentinel lymphadenectomy for melanoma. *Semin Surg Oncol* 1998;14:283-290.

34. Glass EC, Essner R, Morton DL. Kinetics of three lymphoscintigraphic agents in patients with cutaneous melanoma. *J Nucl Med* 1998;39:1185-1190.

35. Haigh PI, Lucci A, Turner RR, et al. Carbon dye histologically confirms the identity of sentinel nodes in cutaneous melanoma. *Cancer* 2001;92:535-541.

36. Cochran AJ, Wen DR, Morton DL. Management of the regional lymph nodes in patients with cutaneous malignant melanoma. *World J Surg* 1992;16:214-221.

37. Leong SP, Steinmetz I, Habib FA, et al. Optimal selective sentinel lymph node dissection in primary malignant melanoma. *Arch Surg* 1997;132:666-673.

38. Morton DL, Thompson JF, Essner R, et al. Validation of the accuracy of intraoperative lymphatic mapping and sentinel lymphadenectomy for early-stage melanoma: a multicenter trial. Multicenter Selective Lymphadenectomy Trial Group. *Ann Surg* 1999;230:453-465.

39. Morton DL, Cochran AJ, Thompson JF, et al. Sentinel node biopsy for early-stage melanoma accuracy and morbidity in MSLT-1, an international multicenter trial. *Ann Surg* 2005;242:302-313.

40. Morton DL, Thompson JF, Cochran AJ, et al. 2005 ASCO Annual Meeting Proceedings. *J Clin Oncol* 2005;23:7500.

41. de Hullu JA, Hollema H, Piers DA, et al. Sentinel lymph node dissection is highly accurate in squamous cell carcinoma of the vulva. *J Clin Oncol* 2000;18:2811-2816.

42. Bilchik AJ, Giuliano A, Essner R, et al. Universal application of intraoperative lymphatic mapping and sentinel lymphadenectomy in solid neoplasms. *Cancer J Sci Am* 1998;4:351-358.

43. Hill AD, Brady MS, Coit DG. Intraoperative mapping and sentinel lymph node biopsy for Merkel cell carcinoma. *Br J Surg* 1999;86:518-521.

44. Wagner JD, Evdokimov DZ, Weisberger E, et al. Sentinel lymph biopsy for high risk non-melanoma cutaneous malignancy. *Arch Dermatol* 2004;140:75-79.

45. Carter CL, Allen C, Henson DE. Relation of tumor size, lymph node status, and survival in 24,740 breast cancer cases. *Cancer* 1989;63:181-187.

46. Fisher ER, Anderson S, Redmond C, et al. Pathologic findings from the National Surgical Adjuvant Breast Project Protocol B-06. 10-year pathologic and clinical prognostic discriminants. *Cancer* 1993;71:2507-2514.

47. Halsted W. The results of operations for the cure of cancer of the breast performed at the Johns

Hopkins Hospital from June, 1889, to January, 1894. *Johns Hopkins Hosp Bull* 1894;4:297-323.

48. Giuliano AE, Kirgan DM, Guenther JM, Morton DL. Lymphatic mapping and sentinel lymphadenectomy for breast cancer. *Ann Surg* 1994;220:391-398.

49. Krag DN, Weaver DL, Alex JC, Fairbank JT. Surgical resection and radiolocalization of the sentinel lymph node in breast cancer using a gamma probe. *Surg Oncol* 1993;2:335-339.

50. Albertini JJ, Lyman GH, Cox C, et al. Lymphatic mapping and sentinel node biopsy in the patient with breast cancer. *JAMA* 1996;276:1818-1822.

51. Giuliano AE, Jones RC, Brennan M, et al. Sentinel lymphadenectomy in breast cancer. *J Clin Oncol* 1997;15:2345-2350.

52. Krag D, Weaver D, Ashikaga T, et al. The sentinel node in breast cancer—a multicenter validation study. *N Engl J Med* 1998;339:941-946.

53. McMasters KM, Tuttle TM, Carlson DJ, et al. Sentinel lymph node biopsy for breast cancer: a suitable alternative to routine axillary dissection in multi-institutional practice when optimal technique is used. *J Clin Oncol* 2000;18:2560-2566.

54. Hsueh EC, Hansen N, Giuliano AE. Intraoperative lymphatic mapping and sentinel lymph node dissection in breast cancer. *CA Cancer J Clin* 2000;50:279-291.

55. Pivoski SP, Olsen JO, Young DC, et al. Prospective randomized trial comparing intradermal, intraparenchymal, and subareolar injection routes for sentinel lymph node mapping and biopsy in breast cancer. *Ann Surg Oncol* 2006;13:S10-S11.

56. Wong SL, Chao C, Edwards MJ, et al. Accuracy of sentinel lymph node biopsy for patients with T2 and T3 breast cancers. *Am Surg* 2001;67:522-526.

57. Bedrosian I, Reynolds C, Mick R, et al. Accuracy of sentinel lymph node biopsy in patients with large primary breast tumors. *Cancer* 2000;88:2540-2545.

58. Chung MH, Ye W, Giuliano AE. Role for sentinel lymph node dissection in the management of large ( $\geq 5$  cm) invasive breast cancer. *Ann Surg Oncol* 2001;8:688-692.

59. Pendas S, Dauway E, Giuliano R, et al. Sentinel node biopsy in ductal carcinoma in situ patients. *Ann Surg Oncol* 2000;7:15-20.

60. Reitsamer R, Peintinger F, Rettenbacher L, et al. Sentinel lymph node biopsy in breast cancer patients after neoadjuvant chemotherapy. *J Surg Oncol* 2003;84:63-67.

61. Mamounas EP, Brown A, Anderson S, et al. Sentinel node biopsy after neoadjuvant chemotherapy in breast cancer: results from National Surgical Adjuvant Breast and Bowel Project Protocol B-27. *J Clin Oncol* 2005;23:2694-2702.

62. Lyman GH, Giuliano AE, Somerfield MR, et al. American Society of Clinical Oncology. American Society of Clinical Oncology guideline recommendations for sentinel lymph node biopsy in early-stage breast cancer. *J Clin Oncol* 2005;23:7703-7720.

63. Sabel MS, Schott AF, Kleer CG, et al. Sentinel node biopsy prior to neoadjuvant chemotherapy. *Am J Surg* 2003;186:102-105.



64. Singletary SE, Connolly JL. Breast cancer staging: working with the sixth edition of the AJCC cancer staging manual. *CA Cancer J Clin* 2006;56:37–47.
65. National Cancer Institute. Phase III randomized study of surgical resection with or without axillary lymph node dissection in women with clinically node-negative breast cancer with sentinel node micrometastases. Available at: <http://www.cancer.gov/clinicaltrials/IBCSG-23-01>. Accessed on April 17, 2006.
66. American College of Surgeons Oncology Group. A prognostic study of sentinel node and bone marrow micrometastases in women with clinical T1 or T2 N0 M0 breast cancer. Available at: [https://www.acosog.org/studies/synopses/Z0010\\_Synopsis.pdf](https://www.acosog.org/studies/synopses/Z0010_Synopsis.pdf). Accessed April 17, 2006.
67. Brogi E, Torres-Matundan E, Tan LK, Cody HS III. The results of frozen section, touch preparation, and cytological smear are comparable for intraoperative examination of sentinel lymph nodes: a study of 133 breast cancer patients. *Ann Surg Oncol* 2005;12:173–180.
68. Cox CE, Furman B, Dupont EL, et al. Novel techniques in sentinel lymph node mapping and localization of nonpalpable breast lesions: the Moffitt experience. *Ann Surg Oncol* 2004;11:222S–2226S.
69. Cox CE, Salud CJ, Cantor A, et al. Learning curves for breast cancer sentinel lymph node mapping based on surgical volume analysis. *J Am Coll Surg* 2001;193:593–600.
70. Tafra L, Lannin DR, Swanson MS, et al. Multicenter trial of sentinel node biopsy for breast cancer using both technetium sulfur colloid and isosulfan blue dye. *Ann Surg* 2001;233:51–59.
71. Veronesi U, Paganelli G, Viale G, et al. A randomized comparison of sentinel-node biopsy with routine axillary dissection in breast cancer. *N Engl J Med* 2003;349:546–553.
72. Swanson RS, Compton CC, Stewart AK, Bland KI. The prognosis of T3N0 colon cancer is dependent on the number of lymph nodes examined. *Ann Surg Oncol* 2003;10:65–71.
73. Le Voyer TE, Sigurdson ER, Hanlon AL, et al. Colon cancer survival in associated with increasing number of lymph nodes analyzed: a secondary survey of Intergroup trial INT-0089. *J Clin Oncol* 2003;21:2912–2919.
74. André T, Boni C, Mounedji-Boudiaf L, et al. Oxaliplatin, fluorouracil, and leucovorin as adjuvant treatment for colon cancer. *N Engl J Med* 2004;350:2343–2351.
75. Benson AB, Schrag D, Somerfield MR, et al. American Society of Clinical Oncology recommendations on adjuvant chemotherapy for stage II colon cancer. *J Clin Oncol* 2004;22:3408–3419.
76. Grothey A, Sargent DJ. FOLFOX for Stage II Colon Cancer? A commentary on the recent FDA approval of oxaliplatin for adjuvant therapy of stage III colon cancer. *J Clin Oncol* 2005;23:3311–3313.
77. Wong JH, Steineman S, Calderia C, et al. Ex vivo sentinel node mapping in carcinoma of the colon and rectum. *Ann Surg* 2001;233:515–521.
78. Wong JH, Johnson DS, Namiki T, et al. Validation of ex vivo lymphatic mapping in hematoxylin-eosin node-negative carcinoma of the colon and rectum. *Ann Surg Oncol* 2004;11:772–777.
79. Tuech JJ, Pessaux P, Di Fiore F, et al. Sentinel node mapping in colon carcinoma: in-vivo versus ex-vivo approach. *Eur J Surg Oncol* 2006;32:158–161.
80. Joosten JJ, Strobbe LJ, Wauters CA, et al. Intraoperative lymphatic mapping and the sentinel node concept in colorectal carcinoma. *Br J Surg* 1999;86:482–486.
81. Bilchik AJ, Saha S, Wiese D, et al. Molecular staging of early colon cancer on the basis of sentinel node analysis: a multicenter phase II trial. *J Clin Oncol* 2001;19:1128–1136.
82. Stojadinovic A, Allen PJ, Protic M, et al. Colon sentinel lymph node mapping: practical surgical applications. *J Am Coll Surg*, 2005;297–313.
83. Bertagnolli M, Miedema B, Redston M, et al. Sentinel node staging of resectable colon cancer: results of a multicenter study. *Ann Surg* 2004;240:624–630.
84. Redston M, Compton CC, Miedema BW, et al. Analysis of micrometastatic disease in sentinel lymph nodes from resectable colon cancer: results of cancer and leukemia group B trial 80001. *J Clin Oncol* 2006;24:878–883.
85. Saha S, Seghal R, Patel M, et al. A multicenter trial of sentinel lymph node mapping in colorectal cancer: prognostic implications for nodal staging and recurrence. *Am J Surg* 2006;191:305–310.
86. Bilchik AJ, DiNome M, Saha S, et al. Prospective multi-center trial of staging adequacy in colon cancer: preliminary results. *Arch Surg* 2006;141:527–534.
87. Braat AE, Oosterhuis JW, Moll FC, et al. Sentinel node detection after preoperative short-course radiotherapy in rectal carcinoma is not reliable. *Br J Surg* 2005;92:1533–1538.
88. Roukos DH. Current status and future perspectives in gastric cancer management. *Cancer Treat Rev* 2000;26:243–245.
89. Tsioulis GJ, Wood TE, Morton DL, Bilchik AJ. Lymphatic mapping and focused analysis of sentinel lymph nodes upstage gastrointestinal neoplasms. *Arch Surg* 2000;135:926–932.
90. Sano T, Katai H, Sasko M, et al. Gastric lymphadenectomy and detection of sentinel nodes. *Recent Results Cancer Res* 2000;157:253–258.
91. De Manzoni G, Verlato G, Guglielmi A, et al. Prognostic significance of lymph node dissection in gastric cancer. *Br J Surg* 1996;83:1604–1607.
92. Siewert JR, Bottcher K, Stein HJ, et al. Relevant prognostic factors in gastric cancer: ten-year results of the German gastric cancer study. *Ann Surg* 1998;228:449–461.
93. Ichikura T, Chochi K, Sugawara H, et al. Individualized surgery for early gastric cancer guided by sentinel node biopsy. *Surgery* 2006;139:501–507.
94. Macdonald JS, Smalley SR, Benedetti J, et al. Chemoradiotherapy after surgery compared with surgery alone for adenocarcinoma of the stomach or gastroesophageal junction. *N Engl J Med* 2001;345:725–730.
95. Kitagawa Y, Fujii H, Kumai K, et al. Recent advances in sentinel node navigation for gastric cancer: a paradigm shift of surgical management. *J Surg Oncol* 2005;90:147–152.
96. Zulfikaroglu B, Koc M, Ozmen MM, et al. Intraoperative lymphatic mapping and sentinel lymph node biopsy using radioactive tracer in gastric cancer. *Surgery* 2005;138:899–904.
97. Kitagawa Y, Fujii H, Mukai M, et al. Sentinel lymph node mapping in esophageal and gastric cancer. *Cancer Treat Res* 2005;127:123–139.
98. Park DJ, Lee HJ, Lee HS, et al. Sentinel node biopsy for cT1 and cT2a gastric cancer. *Eur J Surg Oncol* 2006;32:48–54.
99. Kitagawa Y, Fujii H, Mukai M, et al. The role of the sentinel lymph node in gastrointestinal cancer. *Surg Clin North Am* 2000;80:799–809.
100. Yasuda S, Shimada H, Chino O, et al. Sentinel lymph node detection with Tc-99m tin colloids in patients with esophagogastric cancer. *Jpn J Clin Oncol* 2003;33:68–72.
101. Udagawa H, Akiyama H. Surgical treatment of esophageal cancer: Tokyo experience of the three-field technique. *Dis Esophagus* 2001;14:110–114.
102. Kitagawa Y, Fujii H, Mukai M, et al. Current status and future prospects of sentinel node navigational surgery for gastrointestinal cancers. *Ann Surg Oncol* 2004;11:242S–244S.
103. Udagawa H. Sentinel node concept in esophageal surgery: an elegant strategy. *Ann Thorac Cardiovasc Surg* 2005;11:1–3.
104. Lamb PJ, Griffen SM, Burt AD, et al. Sentinel node biopsy to evaluate the metastatic dissemination of esophageal adenocarcinoma. *Br J Surg* 2005;92:60–67.
105. Alex JC, Sasaki CT, Krag DN, et al. Sentinel lymph node radiolocalization in head and neck squamous cell carcinoma. *Laryngoscope* 2000;110:198–203.
106. Shoaib T, Soutar DS, Prosser JE, et al. A suggested method for sentinel lymph node biopsy in squamous cell carcinoma of the head and neck. *Head Neck* 1999;21:728–733.
107. Stoeckli SJ, Steinert H, Pfaltz M, Schmid S. Sentinel lymph node evaluation in squamous cell carcinoma of the head and neck. *Otolaryngol Head Neck Surg* 2001;125:221–226.
108. Civanto FJ, Gomez C, Duque C, et al. Sentinel node biopsy in oral cavity cancer: correlation with PET scan and immunohistochemistry. *Head Neck* 2003;25:1–9.
109. Barzan L, Sulfaro S, Alberti F, et al. Gamma probe accuracy in detecting the sentinel node in clinically N0 squamous cell carcinoma of the head and neck. *Ann Otol Rhinol Laryngol* 2002;111:794–798.
110. Mozzillo N, Chiesa F, Botti G, et al. Sentinel node biopsy in head and neck cancer. *Ann Surg Oncol* 2001;8:1035–1055.
111. Stoeckli SJ, Pfaltz M, Ross GL, et al. The second international conference on sentinel node biopsy in mucosal head and neck cancer. *Ann Surg Oncol* 2005;12:919–924.
112. Paleri V, Rees G, Arullendran P, et al. Sentinel node biopsy in squamous cell cancer of the oral cavity and oral pharynx: a diagnostic meta-analysis. *Head Neck* 2005;27:739–747.

113. Ross GL, Soutar DS, Gordon MacDonald D, et al. Sentinel node biopsy in head and neck cancer: preliminary results of a multicenter trial. *Ann Surg Oncol* 2004;11:690-696.
114. Ross G, Shoaib T, Soutar D, et al. The use of sentinel node biopsy to upstage the clinically N0 neck in head and neck cancer. *Arch Otolaryngol Head Neck Surg* 2002;128:1287-1291.
115. Ross GL, Soutar D, MacDonald DG, et al. Improved staging of cervical metastasis in clinically negative patients with head and neck squamous cell carcinoma. *Ann Surg Oncol* 2004;11:213-218.
116. Werner JA, Dunne AA, Ramaswamy A, et al. The sentinel node concept in head and neck cancer: solution for the controversies in the N0 neck? *Head Neck* 2004;26:603-611.
117. Kovacs AF, Acker P, Berner U, et al. Sentinel lymph node excision. Treatment method of the N0 neck in patients with oral and oropharyngeal carcinoma. *HNO* 2001;49:646-653.
118. Pitman KT, Johnson JT, Brown ML, Myers EN. Sentinel lymph node biopsy in head and neck carcinoma. *Laryngoscope* 2002;112:2101-2113.
119. Shoaib T, Soutar DS, MacDonald DG, et al. The accuracy of head and neck carcinoma sentinel lymph node biopsy in the clinically N0 neck. *Cancer* 2001;91:2077-2083.
120. Pastore A, Turetta GD, Tarabini A, et al. Sentinel lymph node analysis in squamous cell carcinoma of the oral cavity and oropharynx. *Tumori* 2002;88:S58-S60.
121. Hay ID, Bergstralh EJ, Goellner JR, et al. Predicting outcome in papillary thyroid carcinoma: development of a reliable prognostic scoring system in a cohort of 1779 patients surgically treated at one institution during 1940 through 1989. *Surgery* 1993;114:1050-1058.
122. Shaha AR, Shah JP, Loree TR. Risk group stratification and prognostic factors in papillary carcinoma of thyroid. *Ann Surg Oncol* 1996;3:534-538.
123. Hughes CJ, Shaha AR, Shah JP, Loree TR. Impact of lymph node metastasis in differentiated carcinoma of the thyroid: a matched-pair analysis. *Head Neck* 1996;18:127-132.
124. Scheumann GF, Gimm O, Wegener G, et al. Prognostic significance and surgical management of locoregional lymph node metastases in papillary thyroid cancer. *World J Surg* 1994;18:559-568.
125. Keleman PR, Van Herle AJ, Giuliano AE. Sentinel lymphadenectomy in thyroid malignant neoplasms. *Arch Surg* 1998;133:288-292.
126. Pelizzo MR, Boschini IM, Toniato A, et al. Sentinel node procedure with Patent Blue V dye in surgical treatment of papillary thyroid carcinoma. *Acta Otolaryngol* 2001;121:421-424.
127. McHenry CR, Rosen IB, Walfish PG. Prospective management of nodal metastases in differentiated thyroid cancer. *Am J Surg* 1991;162:353-356.
128. Henry JF, Gramatica L, Denizot A, et al. Morbidity of prophylactic lymph node dissection in the central neck area in patients with thyroid carcinoma. *Langenbecks Arch Surg* 1998;383:167-169.
129. Johnson PR, Sehon J, Li BD. Potential utility of sentinel node biopsy in the original surgical assessment of Hurler cell tumors of the thyroid: 23-year institutional review of Hurler cell neoplasms. *J Surg Oncol* 1999;70:100-102.
130. Dixon E, McKinnon JG, Pasička JL. Feasibility of sentinel node biopsy and lymphatic mapping in nodular thyroid neoplasms. *World J Surg* 2000;24:1396-1401.
131. Haigh PI, Giuliano AE. Sentinel lymph node dissection for thyroid malignancy. *Recent Results Cancer Res* 2000;157:201-205.
132. Arch-Ferrer J, Velazquez D, Fajardo R, et al. Accuracy of sentinel node in papillary thyroid carcinoma. *Surgery* 2001;130:907-913.
133. Fukui Y, Yamakawa T, Taniki T, et al. Sentinel lymph node biopsy in patients with papillary thyroid carcinoma. *Cancer* 2001;92:2868-2874.
134. Gallowitsch HJ, Mikosch P, Kresnik E, et al. Lymphoscintigraphy and gamma probe-guided surgery in papillary thyroid carcinoma: the sentinel lymph node concept in thyroid carcinoma. *Clin Nucl Med* 1999;24:744-746.
135. Rettenbacher L, Sungler P, Gmeiner D, et al. Detecting the sentinel lymph node in patients with differentiated thyroid carcinoma. *Eur J Nucl Med* 2000;27:1399-1401.
136. Catarci M, Zaraca F, Angeloni R, et al. Preoperative lymphoscintigraphy and sentinel lymph node biopsy in papillary thyroid cancer. A pilot study. *J Surg Oncol* 2001;77:21-25.
137. Keller SM, Adak S, Wagner H, Johnson DH. Mediastinal lymph node dissection improves survival in patients with stages II and IIIa non-small cell lung cancer. *Eastern Cooperative Oncology Group. Ann Thorac Surg* 2000;70:358-365.
138. Graham AN, Chan KJ, Pastorino U, et al. Systemic nodal dissection in the intrathoracic staging of patients with non-small cell lung cancer. *J Thorac Cardiovasc Surg* 1999;117:246-251.
139. Izbickei JR, Passlick B, Pantel K, et al. Effectiveness of radical systematic mediastinal lymphadenectomy in patients with resectable non-small cell lung cancer: results of a prospective randomized trial. *Ann Surg* 1998;227:138-144.
140. Wu Y, Huang ZF, Wang SY, et al. A randomized trial of systematic nodal dissection in resectable non-small cell lung cancer. *Lung Cancer* 2002;36:1-6.
141. Kubuschok B, Passlick B, Izbickei JR, et al. Disseminated tumor cells in lymph nodes as a determinant for survival in surgically resected non-small cell lung cancer. *J Clin Oncol* 1999;17:19-24.
142. Osaki T, Oyama T, Gu CD, et al. Prognostic impact of micrometastatic tumor cells in the lymph nodes and bone marrow of patients with completely resectable stage I non-small cell lung cancer. *J Clin Oncol* 2002;20:2930-2936.
143. Little AG, DeHoyos A, Kirgan DM, et al. Intraoperative lymphatic mapping for non-small cell lung cancer: the sentinel node technique. *J Thorac Cardiovasc Surg* 1999;117:220-224.
144. Lardinois D, Brack T, Gaspert A, et al. Bronchoscopic radioisotope injection for sentinel lymph-node mapping in potentially resectable non small-cell lung cancer. *Eur J Cardiothorac Surg* 2003;23:824-827.
145. Liptay MJ, Masters GA, Winchenchester DJ, et al. Intraoperative radioisotope sentinel lymph node mapping in non-small cell lung cancer. *Ann Thorac Surg* 2000;70:384-389.
146. Melfi FM, Chella A, Menconi GF, et al. Intraoperative radioguided sentinel lymph node biopsy in non-small cell lung cancer. *Eur J Cardiothorac Surg* 2003;23:214-220.
147. Faries MB, Bleicher RJ, Ye X, et al. Lymphatic mapping and sentinel lymphadenectomy for primary and metastatic pulmonary malignant neoplasms. *Arch Surg* 2004;139:870-877.
148. Nakagawa T, Minamiya Y, Katayose Y, et al. A novel method for sentinel node mapping using magnetite in patients with non-small cell lung cancer. *J Thorac Cardiovasc Surg* 2003;126:563-567.
149. Nomori H, Horio H, Naruke T, et al. Use of technetium-99m tin colloid for sentinel lymph node identification in non-small cell lung cancer. *J Thorac Cardiovasc Surg* 2002;124:486-492.
150. Nomori H, Watanabe K, Ohtsuka T, et al. In vivo identification of sentinel lymph nodes for abbreviation of mediastinal lymph node dissection. *Lung Cancer* 2004;46:49-55.
151. Pulte D, Li E, Crawford BK, et al. Sentinel lymph node mapping and molecular staging in non-small cell lung carcinoma. *Cancer* 2005;104:1453-1461.
152. Schnidt FE, Woltering EA, Webb WR, et al. Sentinel nodal assessment in patients with carcinoma of the lung. *Ann Thorac Surg* 2002;74:870-874.
153. Sugi K, Fukuda M, Nakamura H, Kaneda Y. Comparison of three tracers for detection sentinel lymph nodes in patients with clinical N0 lung cancer. *Lung Cancer* 2003;39:37-40.
154. Tiffet O, Nicholson A, Khaddage A, et al. Feasibility of the detection of the sentinel lymph node in peripheral non-small cell lung cancer with radio isotopic and blue dye techniques. *Chest* 2005;127:443-448.
155. Yoshimasu T, Miyoshi S, Oura S, et al. Limited mediastinal lymph node dissection for non-small cell lung cancer according to intraoperative histologic examinations. *J Thorac Cardiovasc Surg* 2005;130:241-242.
156. Niikura H, Okamura C, Utsunomiya H, et al. Sentinel lymph node detection in patients with endometrial cancer. *Gynecol Oncol* 2005;92:669-674.
157. Di Stefano AB, Acquaviva G, Garozzo G, et al. Lymph node mapping and sentinel node detection in patients with cervical carcinoma: a 2-year experience. *Gynecol Oncol* 2005;99:671-679.
158. Dhar KK, Woolas RP. Lymphatic mapping and sentinel node biopsy in early vulvar cancer. *BJOG* 2005;112:696-702.
159. Wawroschek F. Prostate lymphoscintigraphy and radio-guided surgery for sentinel node identification in prostate cancer. *Urol Int* 2003;70:303-310.
160. Liedberg F, Chebil G, Davidsson T, et al. Intraoperative sentinel node detection improves nodal staging in invasive bladder cancer. *J Urol* 2006;175:84-88.